



Giant Limbus Vertebra Mimicking a Vertebral Fracture

Vertebral Fraktürü Taklit Eden Dev Limbus Vertebra

Fatih Bağcıer, Hayri Oğul*, Ayhan Kul

Atatürk University Faculty of Medicine, Department of Physical Medicine and Rehabilitation, Erzurum, Turkey

*Atatürk University Faculty of Medicine, Department of Radiology, Erzurum, Turkey

To the editor;

A 58-year-old female patient presented to our clinic with a history of low-back pain radiating to her right and left leg for a year. There was no neuropathic pain. She had no symptoms suggestive of inflammatory back pain. Patient's previous medical history was insignificant. There was no history of trauma, chronic disease, alcohol and substance abuse. Neurological examination revealed a positive straight leg-raising test positive bilateral at 50 degrees on the right and left sides. Both the upper and lower limb muscle strength and sensory examination were within normal limits. Other system physical examination findings were normal. Lumbosacral magnetic resonance imaging revealed grade 1-2 spondylolisthesis at L4-L5 and a large bony fragment over the posteriorsuperior portion of L5 lumbar vertebral body (Figure 1). Anti-inflammatory medications, back bracing for stabilisation and physiotherapy treatment regimen (ultrasound, electric stimulation, hot packs) was recommended. The patient's symptoms and physical examination findings regressed.

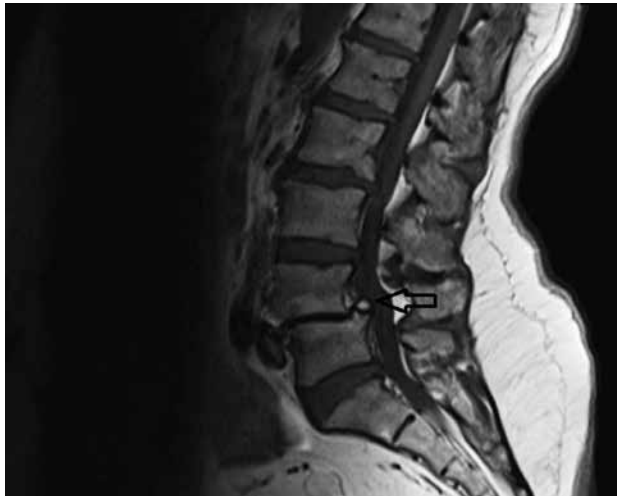


Figure 1. The magnetic resonance imaging of the lumbar spine revealed a large bony fragment over the posteriorsuperior portion of the lumbar vertebral body

Limbus vertebrae results from the marginal disc herniations. The well-shaped triangular bone fragment that is developed by anterior herniation of the nucleus composes the typical form and stands as a separate segment. It has been claimed that the obstructing effect of the replaced disc material from the corpus of the vertebra towards the ring apophysis is responsible for the development of limbus vertebrae (1). Limbus vertebra is not an uncommon radiological finding in an adult, it is a rare finding in the child or adolescent. The most common site for the presence of limbus vertebra is the mid-lumbar region and less commonly occurs in the mid cervical region. Anterior limbus vertebra is typically asymptomatic, while posterior limbus vertebra has been reported to cause nerve compression and is associated with back pain. The limbus vertebra is generally misdiagnosed as a fracture, which may result in unnecessary invasive procedures. The clue for radiographic differentiation of the limbus vertebra from fracture is the sclerotic margin of the triangular fragment. It may be differentiated from an acute fracture because fractures would not have sclerotic margins, but limbus vertebra would (2). Anterior limbus vertebrae are more frequent than posterior limbus vertebrae. A review of literature showed very few reports discussing the limbus vertebrae within the posterior region. Baba et al. (3) reported posterior limbus vertebral lesions causing lumbosacral radiculopathy and the cauda equina syndrome. In our case there was posterior limbus vertebrae mimicking the vertebral fracture. As a result, fractures, degenerative osteophytes and ring epiphysis should be considered as more common etiologies in addition to the acquired developmental fusion defects of vertebra in differential diagnosis of limbus vertebrae.

Keywords: Limbus vertebrae, low back pain, disc herniation

Anahtar kelimeler: Limbus vertebra, bel ağrısı, disk herniasyonu

Author Contributions

Concept: Fatih Bağcıer, Hayri Oğul, Ayhan Kul, Design: Fatih Bağcıer, Hayri Oğul, Ayhan Kul, Data Collection or Processing:

Fatih Bağcıer, Hayri Oğul, Ayhan Kul, Analysis or Interpretation: Fatih Bağcıer, Hayri Oğul, Ayhan Kul, Literature Search: Fatih Bağcıer, Hayri Oğul, Ayhan Kul, Writing: Fatih Bağcıer, Hayri Oğul, Ayhan Kul, Peer-review: Internal peer-reviewed, Conflict of Interest: The authors reported no conflict of interest related to this article, Financial Disclosure: The authors declared that this study has received no financial support.

References

1. Schmorl G, Junghanns H. The human spine in health and disease, 2th ed, New York, Grune&Stratton, 1971.
2. Handel SF, Twiford TW Jr, Reigel DH, Kaufman HH. Posterior lumbar apophyseal fractures. Radiology 1979;130:629-33.
3. Baba H, Uchida K, Furusawa N, Maezawa Y, Azuchi M, Kamitani K, et al. Posterior limbus vertebral lesions causing lumbosacral radiculopathy and the cauda equina syndrome. Spinal Cord 1996;34:427-32.